



## ANGULAR LIMB DEFORMITY CORRECTION

### What is ANGULAR LIMB DEFORMITY?

An angular deformity refers to any condition in which a limb is not straight (excluding fractures). Deformities are typically found in forelimbs and are due to abnormal bone growth or development. The most frequently diagnosed limb deformity in canines is called an angular valgus forelimb deformity (toe pointing outward). It develops secondary to unequal growth between the two bones in the lower forelimb (radius/ulna). This usually arises secondary to a growth plate (regions near the ends and tops of bones responsible for bone growth) injury. When one bone stops growing and the other keeps growing at a normal pace, the abnormal bone (usually the ulna) acts as a tension band causing the growing bone to bow, curve, and/or rotate = deformed limb. The degree of severity is dependent on which bone is affected and patient age. Younger patients, with significant growth potential, typically results in a more severe deformity if left untreated. Severe, untreated deformities often result in poor to complete loss of limb function due to abnormal joint forces resulting in osteoarthritis.

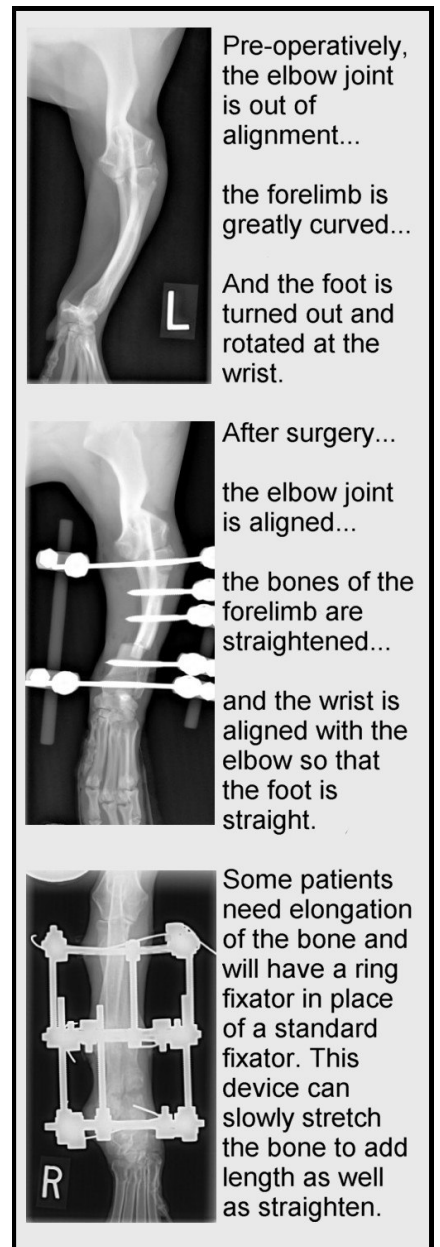
### Diagnosis

Dogs often present with forelimb lameness and the observation of one foot curving out to the side more and more over time. X-rays allow for definitive diagnosis of which bones are affected. The x-rays are also used to help plan the corrective surgery. Sometimes radiographs of the opposite forelimb are needed for comparison purposed to better define the abnormality and plan the corrective procedure

### Treatment

There are two main types of surgical corrections available and their use is primarily dependent on patient age. The first is used in younger patients with significant growth potential remaining. This procedure involves cutting the ulna to release its hold on the radius. This allows the radius to straighten and grow to a normal length.

In dogs closer to skeletal maturity or having little remaining growth potential, a corrective osteotomy is the treatment of choice. This procedure involves cutting both the radius and ulna at the point of greatest radial curvature. The radius is then straightened thereby aligning the elbow and wrist joints. Since both bones have to be cut, the forelimb needs to be stabilized during the healing process. This is typically accomplished with an external skeletal fixator (ESF). In most cases the fixators can be removed in 4-6 weeks. During the healing period, patients need to be strictly confined to a small area and on leash-only activity at all other times. Prognosis is typically very good for long-term normal function assuming that there is no existing arthritis.



For more information visit **Veterinary Specialty & Emergency Care**  
at [www.vetspecialtycare.com](http://www.vetspecialtycare.com)